



DR. PABLO O. TORRE MEMORIAL HOSPITAL

Owned & Operated by Riverside Medical Center, Inc.
B.S Aquino Drive, Bacolod City

Tel. No(s): 4337331 / 705-0000

Summary Statement of Account

Run Datetime: 10/9/2022 10:33:43 AM

Page 1 of 2

Patient Name : **SANTILLANA, CHRISTOPHER DORMIDO**
Patient Address : 86 BALBINA STA CLARA EX. VILLAGE, BARANGAY
MANDALAGAN BACOLOD CITY(CAPITAL) NEGROS
Company :

Admission No. : 191170 Room No. : 439 - 1
Hospital No. : 685423-2009 Rate : 2995.00
Admitted : 10/05/2022 Time : 09:30 PM
Discharged : 10/09/2022 Time :

HOSPITAL BILL PARTICULARS	DEBIT	CREDIT
ROOM CHARGES(3.75 DAY(S),@ 2995.00)	13,477.50	2,246.25
RESPIRATORY THERAPY SERVICES	1,619.35	0.00
MOLECULAR LABORATORY	660.00	0.00
LABORATORY	19,892.30	0.00
PHARMACY MAIN	4,431.68	0.00
EMERGENCY DEPARTMENT	12,162.76	0.00
ADMITTING	145.00	0.00
CENTRAL SUPPLY SERVICES	3,239.23	0.00
NON-INVASIVE CARDIO IMAGING SCIENCES	2,505.00	0.00
DIETARY	245.00	0.00
STATION 6	3,226.00	0.00
X-RAY	965.00	0.00
PHARMACY MAIN(CREDIT NOTE)	0.00	1,519.21
ULTRASOUND	2,565.00	0.00
LABORATORY(CREDIT NOTE)	0.00	540.00
PHILHEALTH BENEFITS	0.00	6,860.00
PAYMENT	0.00	30,000.00
Total Hospital Bill	65,133.82	41,165.46
		23,968.36

OCT 09 2022

COLLECTED UP TO

DATE & TIME

PROFESSIONAL FEES PARTICULARS						
DOCTOR(S)	CHARGES	INSTRU. FEE	DISCOUNT	PAYMENT	PHILHEALTH	BALANCE
CATAYLO, ROSELYN SIALONGO	7,940.00	0.00	0.00	0.00	2,940.00	5,000.00
GAYOLES, M.D. JR., MANUEL Y.	0.00	0.00	0.00	0.00	0.00	0.00
SIA, ANTHONY ORTALIZ	5,000.00	0.00	0.00	0.00	0.00	5,000.00
FRAYCO, M.D., CARINA H.	0.00	0.00	0.00	0.00	0.00	0.00
Total Professional Fee						10,000.00

PHILHEALTH DETAILS	
PARTICULARS	AMOUNT COVERED
ROOM AND BOARD	0.00
DRUGS AND MEDICINE	0.00
XRAY/ LAB / OTHERS	0.00
OPERATING ROOM FEE	0.00
TOTAL AMOUNT	6,860.00

PLEASE PAY THIS AMOUNT

33,968.36

Philhealth Acknowledgement

Signature:
Printed Name:
Relation to Patient:

Verified Correct



RIVERSIDE MEDICAL CENTER, INC.

owner and operator of the Dr. Pablo O. Torre Memorial Hospital and
a proud member of the Metro Pacific Hospital Holdings, Inc.



DEPARTMENT OF IMAGING SCIENCES

Patient Name : **SANTILLANA, CHRISTOPHER DOR.** Document No. : 57469 Run Time : 11:58 am
Birth Date : 01/07/1981 Patient ID : 685423-2009 Run Date : 10/08/2022
Age/Sex/Room : 41 / M / 439 Request Date : 10/07/2022 11:08 AM
Req. Doctor : **SIA, ANTHONY ORTALIZ** Release Date : 10/07/2022 5:53 PM
Encoded By : DAÑOSO, JUNJEE DE ASIS

ABDOMEN

Findings :

UTZ 17-1721
UPPER ABDOMEN ULTRASOUND
Examination Date:10/07/2022

Follow-up examination to the study dated December 10, 2021 shows the following findings:

The liver is normal in size with smooth contour and homogeneous echopattern. There is no focal parenchymal lesion. There is normal branching of the hepatic and portal veins. The intrahepatic ducts and common duct (0.6 cm) are not dilated.

The gallbladder measures 7.7 x 3.6 cm. Its wall is not thickened. A high intensity echo with posterior sonic shadowing measuring 2.7 x 2.1 cm (previously 2.7 x 2.1 cm) is again seen within the lumen.

The pancreas is normal in size with homogeneous echopattern. There is no focal parenchymal lesion. The pancreatic duct is not dilated.


The spleen remains enlarged measuring 13.3 x 6.0 x 12.8 cm with splenic index of 1,021 (previously 808). Parenchymal echopattern is homogeneous. There is no discrete mass lesion.

The aorta and paraaortic areas are unremarkable.

Both kidneys are normal in size and echogenicity with good corticomedullary differentiation. The right kidney measures 11.6 x 4.8 x 5.6 cm with a cortical thickness of 1.2 cm while the left kidney measures 11.4 x 4.6 x 5.5 cm with a cortical thickness of 1.3 cm. The pelvocalyces are not dilated. There is no demonstrable lithiasis or mass lesion.

IMPRESSION :
CHOLECYSTOLITHIASIS.
SPLENOMEGALY.

Radiologic Technologist


ELIZABETH R. HOLLERO, MD, FPCR, FUSP, FCTMRISP

Radiologist



RIVERSIDE MEDICAL CENTER, INC.

owner and operator of the Dr. Pablo O. Torre Memorial Hospital and
a proud member of the Metro Pacific Hospital Holdings, Inc.



DEPARTMENT OF IMAGING SCIENCES

Patient Name : **SANTILLANA, CHRISTOPHER DOR.** Document No. : 57469 Run Time : 11:58 am
Birth Date : 01/07/1981 Patient ID : 685423-2009 Run Date : 10/08/2022
Age/Sex/Room: 41 / M / 439 Request Date : 10/07/2022 11:08 AM
Req. Doctor : **SIA, ANTHONY ORTALIZ** Release Date : 10/07/2022 5:53 PM
Encoded By : DAÑOSO, JUNJEE DE ASIS

ABDOMEN

SONOGRAPHICALLY NORMAL LIVER, PANCREAS, AORTA, PARAAORTIC AREAS AND KIDNEYS.

OFFICIAL

Radiologic Technologist

Elizabeth R. Hollero
ELIZABETH R. HOLLERO, MD, FPCR, FUSP, FCTMRISP

Radiologist



RIVERSIDE MEDICAL CENTER, INC.

owner and operator of the Dr. Pablo O. Torre Memorial Hospital and a proud member of the Metro Pacific Hospital Holdings, Inc.



MOLECULAR BIOLOGY LABORATORY A DOH-Accredited and Licensed COVID-19 Testing Facility License No.: 06-0315-22-H3-2

Patient Name: SANTILLANA, CHRISTOPHER DORMIDO Document No. : 44884 Run Time : 3:22 pm
 Birth Date : 01/07/1981 Patient ID : 685423-2009 Run Date : 10/06/2022
 Age/Gender : 41 / M Specimen No. : 22-13313 Request Date : 10/05/2022 9:36 PM
 Room : OPD Type of Sample: NPS and OPS Collection Date: 10/05/2022 9:35 PM
 Req. Doc : CATAYLO, ROSELYN SIALONGO Release Date : 10/06/2022 2:38 PM

SARS-COV-2 RT-PCR Test

Test Result

NEGATIVE FOR SARS-COV-2 RNA

Interpretation of Results	Target Amplification	Internal Control
POSITIVE FOR SARS-COV-2 RNA	Presence of Typical S-shape amplification at FAM (ORF1ab region) and/or ROX(N gene), Ct ≤ 40	Typical S-Shape Amplification at CY5 (RNase-P) < 40
NEGATIVE FOR SARS-COV-2 RNA	Absence of Typical S-shape amplification curve (No Ct) or CT >40 at FAM and ROX Channel	Amplification curve detected at CY5 (RNase-P) ≤40
INVALID	There is no typical S-shape amplification curve detected at FAM (ORF1b) region, ROX (N gene) and CY5 (RNase-P) (No Ct), or Ct > 40. It is indicated that the specimen's concentration is too low, or there are interfering substances that inhibit the reaction. Repeatedly invalid result recommends repeat sample collection.	

Intended Use Of This Test

Novel Coronavirus (2019-nCoV) Nucleic Acid Diagnostic Kit (PCR-Fluorescence Probing) is used for qualitative detection of ORF1ab and N genes of novel coronavirus (2019-nCoV) in nasopharyngeal swab, oropharyngeal swab and alveolar lavage fluid from suspected pneumonia cases with corona virus infection, patients with suspected clusters of novel coronavirus infection, and other patients requiring diagnosis of novel corona virus infection. Novel Corona Virus(2019-nCoV) Nucleic Acid Diagnostic Kit (PCR-Fluorescence Probing) is only used for the auxiliary diagnosis of related cases and the emergency reserve for in vitro diagnosis during the pneumonia outbreak of Novel Corona Virus (2019-nCoV) and should comply with "Technical Guidelines for Laboratory Testing of Novel Coronavirus by DOH AO 2020-0014 A and B" and other guidelines that shall be mandated by law.

The test results of diagnostic kit can be used for clinical reference. The symptoms and physical signs, disease history, and other laboratory examinations and therapeutic reactions of the patients should be comprehensively considered during their clinical diagnosis. Due to the characteristics of swab and other sample collection process and viral infection process itself, false negative results may be caused by insufficient sample volume, which should be combined with other clinical diagnosis and treatment information, for comprehensive judgment, retest when necessary.

Note

If result is **POSITIVE**, you are strongly advised to seek consult with your Attending Physician.

This examination result does not serve as a medical clearance. You can use the QR Code to validate the result. If QR Code is tampered, this result is considered invalid.

Performed by:

JOHN PAUL P. PANIERGO, RMT
Molecular Biology Laboratory - Analyst
License No. 0098864.

NEIL ROVEN T. TAYSON, RMT
Molecular Biology Laboratory - Analyst
License No. 0075325

Verified by:

MICHELLE ALEXIS G. SO, RMT
Molecular Biology Laboratory - Section Head
License No. 0058618

Encoded by:

ORLANDO JR. S. DELA PEÑA
Molecular Biology Laboratory - Encoder

Validated By:

DAVID G. PEDROZA, MD
Associate Pathologist
License No. 0106055

MELANIE ROSE B. ZERRUDO, MD
Head Pathologist
License No. 0074587

DR. PABLO O. TORRE SR. MEM. HOSPITAL
OWNER/OPERATED BY RIVERSIDE MEDICAL CENTER
B. S. AGUNO DRIVE, BALCOLUD CITY
OCT 08 2022
CERTIFIED TRUE COPY: DATE:
SIGNATURE: [Signature]
(PRINTED NAME)
MEDICAL DEPT.

NOT ADMISSIBLE IN COURT



**DR. PABLO O. TORRE
MEMORIAL HOSPITAL**

B.S. Aquino Drive, Bacolod City
Neg. Occ. 6100, Philippines
Tel. No. (6334) 705-0000
(6334) 433-7331

Fax No. (6334) 434-5532
Website: www.rivermedcenter.net
Email: info@rivermedcenter.net



Patient Name: SANTILLANA, CHRISTOPHER DORMIDO	Patient ID: 685423-2009	Document No.: 45160
Patient Address: 86 BALBINA STA CLARA EX. VILLAGE, BARANGAY MANDALAGAN BACOLOD CITY(CAPITAL) NEGROS OCCIDENTAL 6100	Birth Date: Jan-07-1981	
Doctor Name: CANUEL, M.D., JOHN B.	Gender: M	Case Date: Nov-29-2014
Prepared By:	Age: 41Y8M29D	Room No.: 525
Examination: 2D ECHOCARDIOGRAPHY		Request Date: Dec-01-2014

Concentric left ventricular hypertrophy with adequate wall motion and contraction
 Normal right ventricular dimension with adequate contraction
 Normal right atrial dimension
 Dilated left atrial dimension
 Thickened mitral valve leaflet with mild anterior prolapse. Mitral annular calcification
 Thickened aortic cusps without restriction of motion. Aortic annular calcification
 Structurally normal tricuspid and pulmonic valves with good opening and closing motion
 Normal main pulmonary artery
 No pericardial effusion

COLOR FLOW IMAGING/DOPPLER STUDIES

Mild pulmonic regurgitation
 Normal mitral inflow pattern and mitral annular velocities by tissue Doppler integral
 Normal estimated pulmonary artery systolic pressure

CONCLUSION

Concentric left ventricular hypertrophy with adequate resting systolic function and normal diastolic function
 Dilated left atrial dimension without visible thrombus formation
 Structurally normal valves
 No evidence of shunt
 Normal pulmonary pressure
 Above findings are suggestive of hypertensive cardiovascular disease

FIDELYN D. DELA CRUZ, RRT
 CARDIOVASCULAR NURSE TECHNICIAN

ROSELYN S. CATAYLO, MD, FPCP, FPCC, FPSVM
 VASCULAR CARDIOLOGIST

DR. PABLO O. TORRE SR. MEM. HOSPITAL
 OWNED & OPERATED BY: RIVERSIDE MEDICAL CENTER INC.
 B. S. AQUINO DRIVE, BACOLOD CITY

OCT 08 2022
 CERTIFIED TRUE COPY: DATE: _____
 SIGNATURE: _____
 (PRINTED NAME)

MEDICAL RECORDS DEPT.

NOT ADMISSIBLE IN COURT



RIVERSIDE MEDICAL CENTER, INC.

owner and operator of the Dr. Pablo O. Torre Memorial Hospital and
a proud member of the Metro Pacific Hospital Holdings, Inc.



CLINICAL LABORATORY REPORT SEROLOGY & BLOOD BANKING SECTION

Patient Name	: SANTILLANA, CHRISTOPHER DOR.	Document No.	: 1788550	Run Time	: 11:37 pm
Birth Date	: 01/07/1981	Patient ID	: 685423-2009	Run Date	: 10/07/2022
Age/Gender	: 41 / M			Request Date	: 10/07/2022 11:11 A
Room	: 439			Release Date	: 10/07/2022 2:50 PM
Req. Doc	: SIA, ANTHONY ORTALIZ				

HBS ANTIGEN

HBS Antigen	NONREACTIVE
Method	SOLID PHASE ENZYME IMMUNOASSAY

Remarks

Note: Please consult with your physician regarding the interpretation of this examination result.
 This examination result does not serve as a medical clearance. You can use the QR Code to validate the result.
 If QR Code is tampered, this result is considered invalid.

DR. PABLO O. TORRE SR. MEM. HOSPITAL
 OWNED & OPERATED BY: RIVERSIDE MEDICAL CENTER, INC.
 B. S. AGUIÑO DRIVE, BACOLOD CITY
 CERTIFIED TRUE COPY: DATE OCT 08 2022
 SIGNATURE: _____
 (PRINTED NAME)
 MEDICAL RECORDS DEPT.

NOT ADMISSIBLE IN COURT

Ma. Angela
 Ma. Angela Lanquin Alcantara, RMT
 PRC Lic. No.

Melanie Rose O. Buehafa
 Melanie Rose O. Buehafa - Zerrudo, MD
 PRC Lic. No. 0074587



RIVERSIDE MEDICAL CENTER, INC.

owner and operator of the Dr. Pablo O. Torre Memorial Hospital and
a proud member of the Metro Pacific Hospital Holdings, Inc.

DR. PABLO O. TORRE
MEMORIAL HOSPITAL



CLINICAL LABORATORY REPORT CLINICAL SEROLOGY SECTION

Patient Name	: SANTILLANA, CHRISTOPHER DOR.	Document No.	: 1788550	Run Time	: 11:36 pm
Birth Date	: 01/07/1981	Patient ID	: 685423-2009	Run Date	: 10/07/2022
Age/Gender	: 41 / M			Request Date	: 10/07/2022 11:11 A
Room	: 439			Release Date	: 10/07/2022 2:49 PM
Req. Doc	: SIA, ANTHONY ORTALIZ				

HCV ANTIBODY (QUALITATIVE)

Test Requested	Result
HCV Antibody (Qualitative)	NONREACTIVE
Method	SOLID PHASE ENZYME IMMUNOASSAY

Note: Please consult with your physician regarding the interpretation of this examination result.
This examination result does not serve as a medical clearance. You can use the QR Code to validate the result.
If QR Code is tampered, this result is considered invalid.


DR. PABLO O. TORRE SR. MEM. HOSPITAL
(OWNED) & OPERATED BY: RIVERSIDE MEDICAL CENTER, INC.
8. S. ABUINO DRIVE, BACOLOD CITY


CERTIFIED TRUE COPY; DATE: **OCT 08 2022**

SIGNATURE: _____
(PRINTED NAME)

MEDICAL RECORDS DEPT.

NOT ADMISSIBLE IN COURT


Ma. Angela Lanquin Alcantara, RMT
PRC Lic. No.


Melanie Rose O. Buenafe - Zerrudo, MD
PRC Lic. No. 0074587



RIVERSIDE MEDICAL CENTER, INC.

owner and operator of the Dr. Pablo O. Torre Memorial Hospital and
a proud member of the Metro Pacific Hospital Holdings, Inc.



CLINICAL LABORATORY REPORT SEROLOGY & BLOOD BANKING SECTION

Patient Name	: SANTILLANA, CHRISTOPHER DOR.	Document No.	: 1788549	Run Time	: 11:37 pm
Birth Date	: 01/07/1981	Patient ID	: 685423-2009	Run Date	: 10/07/2022
Age/Gender	: 41 / M			Request Date	: 10/07/2022 11:11 A
Room	: 439			Release Date	: 10/07/2022 2:44 PM
Req. Doc	: SIA, ANTHONY ORTALIZ				

IMX-ANTI HBS

Test Requested	Result	Cut-off Rate	Remarks
IMX-Anti HBS	0.84	10.00	NON-REACTIVE

Remarks: VALUE EQUAL OR GREATER THAN THE CUT-OFF RATE IS CONSIDERED REACTIVE.

Note: Please consult with your physician regarding the interpretation of this examination result.
 This examination result does not serve as a medical clearance. You can use the QR Code to validate the result.
 If QR Code is tampered, this result is considered invalid.

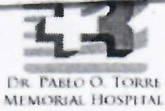DR. PABLO U. TORRE SR. MEM. HOSPITAL
 OWNED & OPERATED BY: RIVERSIDE MEDICAL CENTER INC.
 B. S. ABUINO DRIVE, BACOLOD CITY
 CERTIFIED TRUE COPY! DATE: **OCT 08 2022**
 SIGNATURE: _____

(PRINTED NAME)
MEDICAL RECORDS DEPT.

NOT ADMISSIBLE IN COURT

[Signature]
 Daiden Pechera Saberon - Mangotara, RMT
 PRC Lic No 0061143

[Signature]
 Melanie Rose O/Buehate - Zerrudo, MD
 PRC Lic No 0074587



RIVERSIDE MEDICAL CENTER, INC.

owner and operator of the Dr. Pablo O. Torre Memorial Hospital and
a proud member of the Merro Pacific Hospital Holdings, Inc.



CLINICAL LABORATORY REPORT SEROLOGY & BLOOD BANKING SECTION

Patient Name : SANTILLANA, CHRISTOPHER DOR.	Document No. : 1788549	Run Time : 11:37 pm
Birth Date : 01/07/1981	Patient ID : 685423-2009	Run Date : 10/07/2022
Age/Gender : 41 / M		Request Date : 10/07/2022 11:11 /
Room : 439		Release Date : 10/07/2022 2:46 PM
Req. Doc : SIA, ANTHONY ORTALIZ		

IMX-ANTI HAV IGM

Test Requested	Result	Cut-off Rate	Remarks
IMX-ANTI HAV IGM	0.85	1.20	GRAYZONE REACTIVE

Remarks: VALUE GREATER THAN THE INDEX RATE IS CONSIDERED REACTIVE.

Remarks: It is recommended that patients exhibiting GZR (Gray Zone Reactive) results be closely monitored over time (approximately one week intervals) to distinguish rising IgM anti-HAV levels (associated with acute Hepatitis A infection) from falling or unchanging IgM anti HAV levels (associated with recovery).

Note: Please consult with your physician regarding the interpretation of this examination result.

This examination result does not serve as a medical clearance. You can use the QR Code to validate the result. If QR Code is tampered, this result is considered invalid.

DR. PABLO O. TORRE SR. MEM. HOSPITAL
OWNED & OPERATED BY: RIVERSIDE MEDICAL CENTER, INC.
B. S. ABUINO DRIVE, BACOLOD CITY
CERTIFIED TRUE COPY: DATE: OCT 08 2022
SIGNATURE: *[Signature]*
(PRINTED NAME)

MEDICAL RECORDS DEPT.

NOT ADMISSIBLE IN COURT

[Signature]
Pauline Loren Encia Barbosa, RMT
PRC Lic. No. 0076572

[Signature]
Melanie Rose O/Buehafa - Zerrudo, MD
PRC Lic. No. 0074587



RIVERSIDE MEDICAL CENTER, INC.

owner and operator of the Dr. Pablo O. Torre Memorial Hospital and
a proud member of the Metro Pacific Hospital Holdings, Inc.



CLINICAL LABORATORY REPORT CLINICAL CHEMISTRY SECTION

Patient Name	: SANTILLANA, CHRISTOPHER DOR.	Document No.	: 1788225	Run Time	: 9:32 am
Birth Date	: 01/07/1981	Patient ID	: 685423-2009	Run Date	: 10/07/2022
Age/Gender	: 41 / M			Request Date	: 10/06/2022 1:36 PM
Room	: 439			Release Date	: 10/07/2022 9:02 AM
Req. Doc	: CATAYLO, ROSELYN SIALONGO			Specimen	:

CLINICAL CHEMISTRY

Test Requested	Result (s.i.)	Normal Values (s.i.)	Result (c.u.)	Normal Values (c.u.)
Triglycerides	4.19	0.40 - 1.50 mmol/L	380.91	36.36 - 136.36 mg/dL
Cholesterol	6.04	0.00 - 5.20 mmol/L	232.31	0.00 - 200.00 mg/dL
HDL Cholesterol	1.00	0.91 - 1.60 mmol/L	38.46	35.00 - 61.54 mg/dL
LDL Cholesterol	3.14	0.00 - 3.90 mmol/L	120.77	0.00 - 150.00 mg/dL

Note: Please consult with your physician regarding the interpretation of this examination result.

This examination result does not serve as a medical clearance. You can use the QR Code to validate the result.

If QR Code is tampered, this result is considered invalid.

DR. PABLO O. TORRE SR. MEM. HOSP. PA
OWNED & OPERATED BY: RIVERSIDE MEDICAL CENTER INC.
B. S. AGUIÑO DRIVE, BACOLOD CITY

CERTIFIED TRUE COPY: DATE OCT 08 2022

SIGNATURE: _____
(PRINTED NAME)

MEDICAL RECORDS DEPT.

** Report Electronically Signed Out **

Liza Mae Billeran Paltriguera, RMT
PRC Lic. No. 0059612
Medical Technologist

Melanie Rose O. Buenafe - Zerrudo, MD
PRC Lic. No. 0074587
Pathologist

NOT ADMISSIBLE IN COURT



RIVERSIDE MEDICAL CENTER, INC.

owner and operator of the Dr. Pablo O. Torre Memorial Hospital and
a proud member of the Metro Pacific Hospital Holdings, Inc.



CLINICAL LABORATORY REPORT SEROLOGY SECTION

Patient Name : SANTILLANA, CHRISTOPHER DOR.	Document No. : 869170	Run Time : 11:25 pm
Birth Date : 01/07/1981	Patient ID : 685423-2009	Run Date : 10/05/2022
Age/Gender : 41 / M		Request Date : 10/05/2022 9:35 PM
Room : OPD		Release Date : 10/05/2022 10:52 PM
Req. Doc : CATAYLO, ROSELYN SIALONGO		

TROPONIN I QUANTITATIVE

	Test Requested	Result
	Result	17.9
Normal Value:	Male	equal or less than 34.2 ng/L

Note: Please consult with your physician regarding the interpretation of this examination result.
This examination result does not serve as a medical clearance. You can use the QR Code to validate the result.
If QR Code is tampered, this result is considered invalid.

DR. PABLO O. TORRE SR. MEM. HOSPITAL
OWNED & OPERATED BY: RIVERSIDE MEDICAL CENTER, INC.
B. S. ABUINO DRIVE, BACOLOD CITY

CERTIFIED TRUE COPY: DATE

OCT 08 2022

SIGNATURE

(PRINTED NAME)

MEDICAL RECORDS DEPT.

NOT ADMISSIBLE IN COURT

Jehzeel Genolos Palacios, RMT

Melanie Rose O Buehate - Zerrudo, MD

REC No. 0074587



RIVERSIDE MEDICAL CENTER, INC.

owner and operator of the Dr. Pablo O. Torre Memorial Hospital and
a proud member of the Metro Pacific Hospital Holdings, Inc.



CLINICAL LABORATORY REPORT HEMATOLOGY SECTION

Patient Name	: SANTILLANA, CHRISTOPHER DOR.	Document No.	: 859188	Run Time	: 11:10 am
Birth Date	: 01/07/1981	Patient ID	: 685423-2009	Run Date	: 10/06/2022
Age/Gender	: 41 / M			Request Date	: 10/05/2022 11:20 F
Room	: 439			Release Date	: 10/05/2022 11:53 F
Req. Doc	: CATAYLO, ROSELYN SIALONGO			Specimen	: Blood

COMPLETE BLOOD COUNT

Test Requested	Result	Normal Values
Hemoglobin	177	120.00 - 170.00 g/L
Hematocrit	0.50	0.40 - 0.54
RBC Count	5.42	4.00 - 5.50 x10 ¹² /L
WBC Count	5.6	5.00 - 10.00 x10 ⁹ /L

Differential Count :

Neutrophil	0.64	0.50 - 0.70
Lymphocyte	0.21	0.20 - 0.40
Eosinophil	0.01	0.00 - 0.05
Monocytes	0.13	0.00 - 0.09
Basophil	0.01	0.00 - 0.01

MCH	32.70	26.00 - 34.00 pg
MCHC	35.30	32.00 - 38.00 g/dL
MCV	92.60	82.00 - 98.00 fl
RDW-CV	12.1	11.00 - 16.00 %
P-LCR	36.3	15.00 - 35.00 %
PDW	14.8	9.00 - 14.00 fl
RDW-SD	42.2	37.00 - 46.00 fl
MPV	11.4	8.00 - 12.00 fl
Platelet	109	150.00 - 400.00 x10 ⁹ /L

Note: Please consult with your physician regarding the interpretation of this examination result.
 This examination result does not serve as a medical clearance. You can use the QR Code to validate the result.
 If QR Code is tampered, this result is considered invalid.

DR. PABLO O. TORRE SR. MEM. HOSP.
 OWNED & OPERATED BY: RIVERSIDE MEDICAL CENTER, INC.
 OCT 08 2022
 CERTIFIED TRUE COPY. DATE: _____
 SIGNATURE: _____
 (PRINTED NAME)

MEDICAL RECORDS DEPT
 NOT ADMISSIBLE IN COURT



DR. PABLO O. TORRE
MEMORIAL HOSPITAL

RIVERSIDE MEDICAL CENTER, INC.

owner and operator of the Dr. Pablo O. Torre Memorial Hospital and
a proud member of the Metro Pacific Hospital Holdings, Inc.



CLINICAL LABORATORY REPORT IMMUNOLOGY and SEROLOGY

Patient Name	: SANTILLANA, CHRISTOPHER DORMIDO	Document No.	: 44883	Run Time	: 1:08 am
Birth Date	: 01/07/1981	Patient ID	: 685423-2009	Run Date	: 10/06/2022
Age/Gender	: 41 / M			Request Date	: 10/05/2022 9:35 PM
Room	: 439			Release Date	: 10/05/2022 10:14 F
Req. Doc	: CATAYLO, ROSELYN SIALONGO				

COVID-19 RAPID ANTIGEN (LATERAL FLOW-FDA-APPROVED)

Test Requested	Result
Covid-19 Antigen	NEGATIVE

Note: COVID-19 Rapid Rapid-based test should not be the sole basis for the diagnosis ;RT-PCR test should still be requested.

Only medical doctors can prescribe and interpret results of rapid antigen-based test

DR. PABLO O. TORRE SR. MEM. HOSPITAL
OWNED & OPERATED BY: RIVERSIDE MEDICAL CENTER
B. S. AGUIÑO DRIVE, BACOLOD CITY

CERTIFIED TRUE COPY: DATE: OCT. 08 2022

SIGNATURE: _____
(PRINTED NAME)

MEDICAL RECORDS DEPT.

NOT ADMISSIBLE IN COURT

Tanya Berita Tizon Rufin, RMT

PRC Lic. No. 0098857

Melanie Rose O. Buehafa - Zerrudo, MD

PRC Lic. No. 0074587



RIVERSIDE MEDICAL CENTER, INC.

owner and operator of the Dr. Pablo O. Torre Memorial Hospital and
a proud member of the Metro Pacific Hospital Holdings, Inc.



CLINICAL LABORATORY REPORT CLINICAL CHEMISTRY SECTION

Patient Name	: SANTILLANA, CHRISTOPHER DOR.	Document No.	: 869186	Run Time	: 4:14 am
Birth Date	: 01/07/1981	Patient ID	: 685423-2009	Run Date	: 10/06/2022
Age/Gender	: 41 / M			Request Date	: 10/05/2022 11:20 F
Room	: 439			Release Date	: 10/06/2022 1:10 AM
Req. Doc	: CATAYLO, ROSELYN SIALONGO			Specimen	:

CLINICAL CHEMISTRY

Test Requested	Result (s.i.)	Normal Values (s.i.)	Result (c.u.)	Normal Values (c.u.)
Sodium	135.20	136.00 - 145.00 mmol/L	135.20	136.00 - 145.00 mmol/L
Potassium	4.69	3.50 - 5.50 mmol/L	4.69	3.50 - 5.50 mmol/L
Creatinine	81.20	71.00 - 133.00 umol/L	0.92	0.80 - 1.50 mg/dL
ALT/SGPT	114.00	Less than 50 U/L	114.00	Less than 50 U/L
Uric Acid	0.328	0.20 - 0.40 mmol/L	5.56	3.39 - 6.78 mg/dL

Note: Please consult with your physician regarding the interpretation of this examination result.
 This examination result does not serve as a medical clearance. You can use the QR Code to validate the result.
 If QR Code is tampered, this result is considered invalid.

DR. PABLO O. TORRE SR. MEM. HOSPITAL
 OWNED & OPERATED BY: RIVERSIDE MEDICAL CENTER, INC.
 8. S. AGUIÑO DRIVE, BACOLOD CITY
 CERTIFIED TRUE COPY: DATE **OCT 08 2022**
 SIGNATURE: _____

(PRINTED NAME)

MEDICAL RECORDS DEPT.

NOT ADMISSIBLE IN COURT

(R) Dr. Magbanwa

Jehzeel Geholos Palacios, RMT

PRC Lic No 0098841

Melanie Rose O/Buenafe - Zerrudo, MD

PRC Lic No 0074587



DR. PABLO O. TORRE
MEMORIAL HOSPITAL

RIVERSIDE MEDICAL CENTER, INC.

owner and operator of the Dr. Pablo O. Torre Memorial Hospital and
a proud member of the Metro Pacific Hospital Holdings, Inc.



CLINICAL LABORATORY REPORT CLINICAL CHEMISTRY SECTION

Patient Name	: SANTILLANA, CHRISTOPHER DOR.	Document No.	: 869187	Run Time	: 4:13 am
Birth Date	: 01/07/1981	Patient ID	: 685423-2009	Run Date	: 10/06/2022
Age/Gender	: 41 / M			Request Date	: 10/05/2022 11:20 F
Room	: 439			Release Date	: 10/06/2022 1:09 AM
Req. Doc	: CATAYLO, ROSELYN SIALONGO			Specimen	:

CLINICAL CHEMISTRY

Test Requested	Result (s.i.)	Normal Values (s.i.)	Result (c.u.)	Normal Values (c.u.)
Glycohemoglobin	5.9	4.30 - 6.40 %	5.90	4.30 - 6.40 %

Note: Please consult with your physician regarding the interpretation of this examination result.
 This examination result does not serve as a medical clearance. You can use the QR Code to validate the result.
 If QR Code is tampered, this result is considered invalid.

DR. PABLO O. TORRE SR. MEM. HOSPITAL
 OWNED & OPERATED BY: RIVERSIDE MEDICAL CENTER, INC.
 8. S. AGUINO DRIVE, BACOLOD CITY
 CERTIFIED TRUE COPY: DATE: **OCT 08 2022**
 SIGNATURE: _____
 (PRINTED NAME)

MEDICAL RECORDS DEPT

NOT ADMISSIBLE IN COURT

Dr. Magbanua

Jehzeel Genolos Palacios, RMT
PRC Lic. No. 0098841

Melanie Rose O/Buehafa - Zerrudo, MD
PRC Lic. No. 0074587